



The Journal of Threatened Taxa (JoTT) is dedicated to building evidence for conservation globally by publishing peer-reviewed articles online every month at a reasonably rapid rate at [www.threatenedtaxa.org](http://www.threatenedtaxa.org). All articles published in JoTT are registered under [Creative Commons Attribution 4.0 International License](https://creativecommons.org/licenses/by/4.0/) unless otherwise mentioned. JoTT allows unrestricted use, reproduction, and distribution of articles in any medium by providing adequate credit to the author(s) and the source of publication.

# Journal of Threatened Taxa

Building evidence for conservation globally

[www.threatenedtaxa.org](http://www.threatenedtaxa.org)

ISSN 0974-7907 (Online) | ISSN 0974-7893 (Print)

## COMMUNICATION

### BONE FRACTURES IN ROADKILL NORTHERN TAMANDUA *TAMANDUA MEXICANA* (MAMMALIA: PILOSA: MYRMECOPHAGIDAE) IN COSTA RICA

Randall Arguedas, Elisa C. López & Lizbeth Ovarés

26 November 2019 | Vol. 11 | No. 14 | Pages: 14802–14807

DOI: 10.11609/jott.4956.11.14.14802-14807



For Focus, Scope, Aims, Policies, and Guidelines visit <https://threatenedtaxa.org/index.php/JoTT/about/editorialPolicies#custom-0>  
For Article Submission Guidelines, visit <https://threatenedtaxa.org/index.php/JoTT/about/submissions#onlineSubmissions>  
For Policies against Scientific Misconduct, visit <https://threatenedtaxa.org/index.php/JoTT/about/editorialPolicies#custom-2>  
For reprints, contact [ravi@threatenedtaxa.org](mailto:ravi@threatenedtaxa.org)

The opinions expressed by the authors do not reflect the views of the Journal of Threatened Taxa, Wildlife Information Liaison Development Society, Zoo Outreach Organization, or any of the partners. The journal, the publisher, the host, and the partners are not responsible for the accuracy of the political boundaries shown in the maps by the authors.

#### Partner



صندوق محمد بن زايد  
للمحافظة على  
الكائنات الحية  
The Mohamed bin Zayed  
SPECIES CONSERVATION FUND

#### Member



#### Publisher & Host





ISSN 0974-7907 (Online)  
ISSN 0974-7893 (Print)

PLATINUM  
OPEN ACCESS



Journal of Threatened Taxa | www.threatenedtaxa.org | 26 November 2019 | 11(14): 14802–14807

# BONE FRACTURES IN ROADKILL NORTHERN TAMANDUA *TAMANDUA MEXICANA* (MAMMALIA: PILOSA: MYRMECOPHAGIDAE) IN COSTA RICA

Randall Arguedas<sup>1</sup> , Elisa C. López<sup>2</sup> & Lizbeth Ovares<sup>3</sup>

<sup>1,3</sup> Zoológico Nacional Simón Bolívar, Barrio Amón, Calle 13, San José 11594-1000, Costa Rica.

<sup>2</sup> Parque Ecológico Totlali, Guerrero s/n, San Pablo Tejalpa, Zumpahuacán, Estado de México 51986, México.

<sup>1</sup> ranarg@gmail.com (corresponding author), <sup>2</sup> mvz.elisa.lopez@totlali.com, <sup>3</sup> liz.ovares@gmail.com

**Abstract:** Northern Tamandua *Tamandua mexicana* is one of the most common roadkill species encountered on Costa Rican highways. Ten roadkill Northern Tamanduas were collected along different roads in Costa Rica and moved to a veterinary facility where appendicular radiologic studies were undertaken. The number of fractures present in each individual varied from zero to five (mean=2.6), with only one animal sustaining no fractures at all. Most fractures were present in the humerus (31%), followed by the ulna and ilium (both 19%), whilst the cranial portion of the body represented the highest number of fractures (61%). These data can contribute, not only to establishing causes of animal-road-mortalities, but also to the future understanding and decision-making of clinical actions for animals injured on the roads.

**Keywords:** Anteater, car accidents, radiology, roadways, wildlife mortality.

**Resume:** El tamandú norteco *Tamandua mexicana* es una de las especies que más comunes que se encuentran atropelladas en las carreteras de Costa Rica. Se recolectaron diez tamandúes atropellados a lo largo de diferentes caminos en Costa Rica y se trasladaron a una clínica veterinaria donde se realizaron estudios radiológicos apendiculares. El número de fracturas presentes en cada individuo varió de cero a cinco (media = 2.6), y solo un animal no sufrió fracturas del todo. La mayoría de las fracturas estaban presentes en el humero (31%), seguidas por la ulna y el ilion (ambos 19%); la porción craneal del cuerpo representaba el mayor número de fracturas (61%). Estos datos pueden contribuir, no solo al establecimiento de causas de mortalidad de animales en el camino, sino también a la comprensión y toma de decisiones futuras de acciones médicas para animales que son heridos en carreteras

**DOI:** <https://doi.org/10.11609/jott.4956.11.14.14802-14807>

**Editor:** Wendy Collinson-Jonker, Endangered Wildlife Trust, Gauteng, South Africa.

**Date of publication:** 26 November 2019 (online & print)

**Manuscript details:** #4956 | Received 18 March 2019 | Final received 02 November 2019 | Finally accepted 05 November 2019

**Citation:** Arguedas, R., E.C. Lopez & L. Ovares (2019). Bone fractures in roadkill Northern Tamandua *Tamandua mexicana* (Mammalia: Pilosa: Myrmecophagidae) in Costa Rica. *Journal of Threatened Taxa* 11(14): 14802–14807. <https://doi.org/10.11609/jott.4956.11.14.14802-14807>

**Copyright:** © Arguedas et al. 2019. Creative Commons Attribution 4.0 International License. JoTT allows unrestricted use, reproduction, and distribution of this article in any medium by adequate credit to the author(s) and the source of publication.

**Funding:** Authors used their own resources for this project.

**Competing interests:** The authors declare no competing interests.

**Author details:** RANDALL ARGUEDAS—Zoo and wildlife veterinarian and Master of Science degree on Conservation Medicine. Head veterinarian at the Zoológico Nacional Simón Bolívar. Professor of Zoo and wildlife medicine and surgery at Universidad Técnica Nacional. Research interests are mainly on baseline physiology, anatomy and diseases of wild vertebrates. ELISA C. LÓPEZ—Veterinarian and general manager at Totlali Ecological Park and legal representative of the National Registry of Scientific and Technological Institutions and Companies (RENIECYT). Currently working on the “Etnobiological Garden” research at the Totlali Ecological Park. LIZBETH OVARES—Tropical biologist. Head of the Environmental Education Department at the Zoológico Nacional Simón Bolívar. Research interests are in wildlife urban ecology and human interactions with wildlife.

**Author contribution:** RA—conceived and designed the study, took the X-rays, analyzed and interpreted data and wrote the paper. ECL—helped in the study design, field, took the X-rays, edited the X-ray images. LO—analyzed and interpreted data, wrote the paper.

**Acknowledgements:** Dr. Alejandro Gómez, Dr. Ricardo García, and Dr. Natalia Pérez, for facilitating all the x-rays. All the staff from Vías Amigables con la Vida Silvestre Costa Rica.



## INTRODUCTION

Highways are significant factors of wildlife mortality; they interfere with natural migration routes and are responsible for habitat fragmentation, which is one of the main causes of biodiversity loss (De la Ossa-V & Galván-Guevara 2015). A further negative impact of roads is the resulting collision with a vehicle, namely, roadkill.

Studies have shown that roadkill seriously decreases animal populations and can even result in local extinctions creating a risk factor for xenarthran persistence, even to non-threatened species (Ribeiro et al. 2017). Among Costa Rican wildlife species, the Common Opossum *Didelphis marsupialis* and a species of anteater *Tamandua mexicana* (Image 1) dominate roadkill numbers (Monge-Nágera 2018b).

Monge-Nágera (2018a) found that *T. mexicana* was the most common roadkill species ( $n=73$ ), followed by the Common Opossum ( $n=66$ ) from data gathered over a four year period (2014–2018). Furthermore, 13 additional *T. mexicana* individuals were detected as roadkill over a one-year period (48 sample efforts) on a 94.9km road ( $n=7.3$  anteater/km) (Artavia et al. 2015) whilst a further seven individuals of *T. mexicana* were

found on a 100-km section of road over an eight-month period in 2008 (Carvajal Alfaro & Díaz Quesada 2016).

*T. mexicana* had higher numbers of roadkill during the dry season (December to April) than the wet season (May to November) in Costa Rica and Colombia (Nadjar & De la Ossa 2013; Monge-Nágera 2018a) possibly because ants are scarcer in dryer habitats than when it is wet, causing anteater species to travel further in search of food. This may result in them crossing roads more frequently and becoming roadkill although this is just speculation since the seasonal behavior of *T. mexicana* is poorly known (Nadjar & De la Ossa 2013; Monge-Nágera 2018a) and further study of their behaviour is needed (Monge-Nágera 2017, 2018a).

Descriptive epidemiological studies of wildlife are an important source of information about natural and non-natural hazards to wildlife populations (Molina-López et al. 2011) and consequently, studies that investigate the causes of mortality have become an important source for ecosystem health monitoring (Molina-López et al. 2011). One of the most common findings in animals hit by automobiles is the appendicular fractures (Minar et al. 2013) which can be surgically treated if an injured animal is taken to a rescue center. Understanding the normal



Image 1. Northern Tamandua *Tamandua mexicana* at Aranjuez, Pitahaya, Puntarenas Province, Costa Rica.



bone radiographic appearance as well as the location of the fracture is vital in assisting the treatment of injured animals. Furthermore, increased public awareness of the number of wildlife injured or killed on Costa Rican roads may have contributed to the mitigation methods being applied.

*T. mexicana* is a species of a medium-sized anteater ranging from southern Mexico to northwestern Andes in South America and lives in diverse forest ecosystems (Navarrete & Ortega 2011). It is classified as “Least Concern” by the IUCN due to its wide distribution, and presumably, large population, however, the current population trend is unknown (Ortega et al. 2014), although it is represented in protected areas, as well as in anthropogenic ecosystems (Navarrete & Ortega. 2011). Usually solitary by nature, *T. mexicana* ranges often overlap with that of neighboring *T. mexicana*. Females give birth to a single offspring once a year, with the pups becoming independent after one year (Wainwright 2007; Navarrete & Ortega. 2011). Head and body length ranges from between 470–770 mm, with a tail length between 402–672 mm; weight ranges from 2–7 kg (Nowak 1991; Wainwright 2007). *T. mexicana* is both diurnal and nocturnal foraging in trees and on the ground, feeding predominantly on termite genera: (*Armitermes*, *Calcaritermes*, *Coptotermes*, *Leucotermes*, *Microcerotermes*, and *Nasutitermes*; Navarrete & Ortega 2011) and ant genera (*Camponotus*, *Azteca*, and *Crematogaster*; Navarrete & Ortega 2011)

The purpose of this communication is to use roadkill *T. mexicana* as tools to demonstrate the location and frequency of bone fractures resulting from an impact with a vehicle. This information can be a valuable reference in future medical and surgical procedures at rescue centers.

## METHODS

Ten roadkill of *T. mexicana* were collected between April to July 2016, on different roads in Costa Rica. For each individual, the date and time of collection, geographic coordinates and the person responsible for collecting them were recorded. We believe that two of the animals were at least one year old. The remaining eight individuals consisted of mature animals based on closed epiphyseal growth plates. Based on the presence of the reproductive organs, we were able to sex three of the *T. Mexicana* confirming there were two females and one male; three of the carcasses had no organs, whilst the remaining four individuals were unclear due

to damage to the abdominal cavity.

The 10 *T. Mexicana* (all deceased) were transferred to a veterinary establishments where appendicular radiology studies were carried out using an Ultra 12040HF (Diagnostic Imaging Systems®) X-ray unit with a CR2000 Plus Scanner and CR200 Navigator Software (Diagnostic Imaging Systems®). Lateral (L) and anteroposterior (AP) orthogonal views of the four extremities were taken. Each animal received six radiographs, with AP projections of the forelimbs and hind limbs performed on both limbs at the same time. Each affected bone, in all animals, had only one fracture, which made further classification easier. For two of the animals, x-rays of the hind legs could not be done due to extensive damage to the legs. For the remaining eight, x-rays of the forelimbs (including the scapula, humerus, radius/ulna, carpus, metacarpals, and phalanges) and x-rays of the hind limbs (including the ilium, ischium, pubis, femur, tibia and fibula, tarsals, metatarsals and phalanges) were all taken.

## RESULTS

Of the 10 roadkill, a total of 54 radiographs were taken (Figures 1 & 2). Two individuals had open epiphyseal growth lines indicating that they were juveniles and still growing. The number of fractures present in each individual varied from zero to five (mean=2.6); only one animal did not present any fractures, while three of them had a total of five fractures in different bones (Table 1). Sixty-one percent of the fractures occurred in the cranial portion of the body with the majority observed in the humerus (31%) followed by the ulna (19%) and then the radius (11%). The remaining 39% were present in the caudal portion of the body with the majority observed in the ilial (19%), followed by the femur (12%) and then tibia/fibula (8%); no fractures were observed in the scapula, ischium, pubis, carpal/tarsal, metacarpal/tarsal and phalanges.

## DISCUSSION

There are few studies that utilize road-killed animals as a beneficial tool for learning, specifically for evaluating fractures on animal-roadkill species. Most studies that evaluate roadkill-animal-fractures mainly focus on domestic animals (for example, dogs and cats) (Minar et al. 2013; Martínez-Hernández et al. 2017). Despite cats having a similar head and body length (that is, ~460mm) as the *T. mexicana*, our study observed that a higher

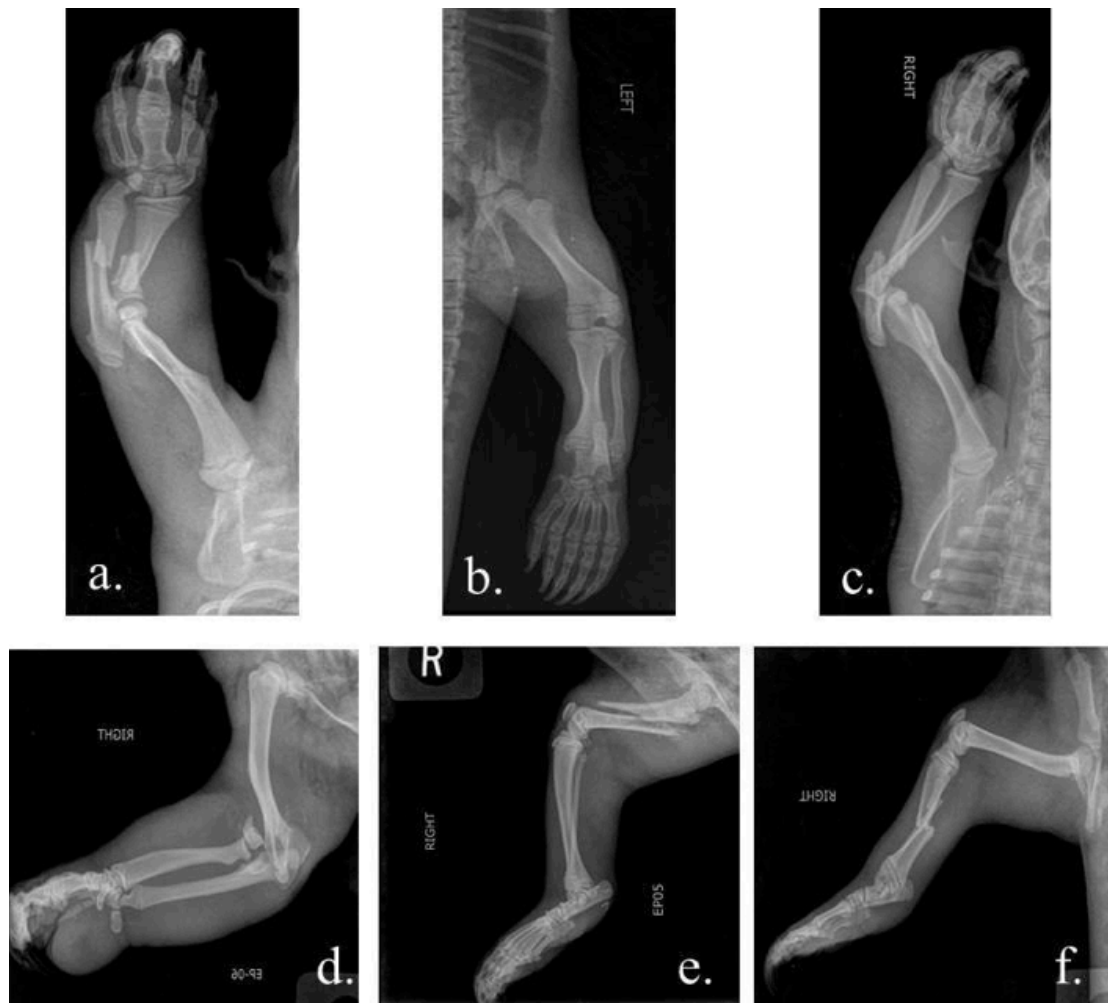
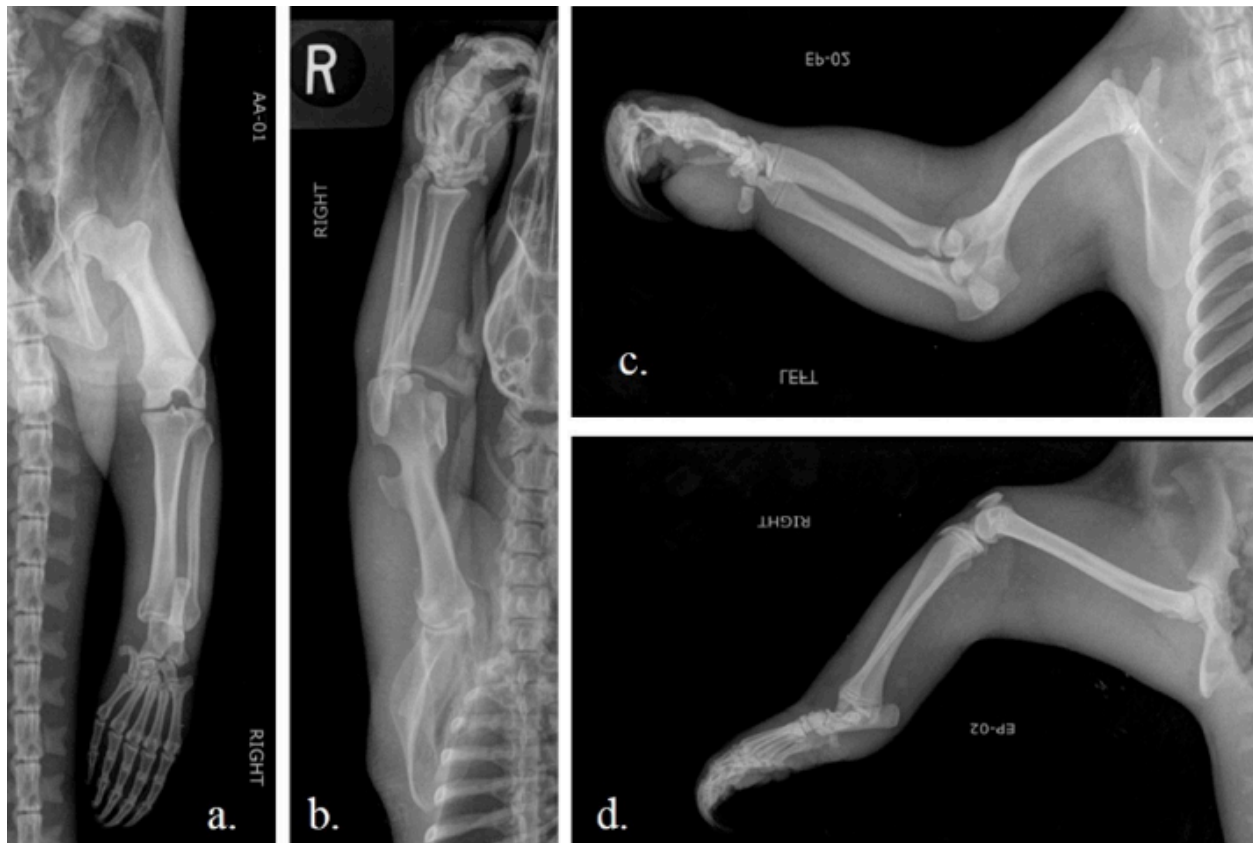
Figure 1. Selected x-rays of fractures in different bones from the ten roadkill *T. mexicana* collected between April and July 2016, on different roads in Costa Rica. Anteroposterior and lateral projections are represented. a—diaphyseal radio-ulnar fracture | b—distal ilial fracture | c—distal humeral fracture | d—distal humeral fracture | e—diaphyseal femoral fracture | f—diaphyseal tibial fracture

Table 1. Fractures per individual of the ten roadkill *T. mexicana* collected between April to July 2016, on different roads in Costa Rica.

Individual	Affected bone												Total
	LH	RH	LR	RR	LU	RU	LF	RF	LT	RT	LI	RI	
T1	-	-	-	-	-	-	-	-	-	-	-	-	0
T2	-	1	-	1	-	1	-	-	-	1	-	1	5
T3	1	-	-	-	-	-	-	-	-	-	-	-	1
T4	-	-	-	-	-	1	-	-	-	1	1	-	3
T5	1	1	1	1	1	-	x	x	x	x	x	x	5
T6	-	-	-	-	-	1	-	1	-	-	-	-	2
T7	-	-	-	-	-	-	-	-	-	-	1	-	1
T8	-	1	-	-	1	-	x	x	x	x	x	x	2
T9	1	1	-	-	-	-	-	1	-	-	1	1	5
T10	-	1	-	-	-	-	-	1	-	-	-	-	2
Total overall	3	5	1	2	2	3	0	3	0	2	3	2	25

Key: L—left | R—right | H—humerus | R—radius | U—ulna | F—femur | T—tibia | I—ilium. Individuals T5 and T8 have no hind limb x-rays (x) | —means no fractures | X—means the individuals did not have the limb.



**Figure 2.** Four X-rays of complete *T. mexicana* normal extremities. Anteroposterior (AP) and lateral projections (L) are represented. a—AP projection of the pelvic limb | b—AP projection of the thoracic limb | c—L projection of the thoracic limb | d—L projection of the pelvic limb.

percentage of fractures were found in the cranial portion of the *T. mexicana* whilst the most commonly affected bones in cats were found in the caudal portion (such as, the femur (28.2%) and pelvis (24.8%). The same contrast was also noticed with dogs with more fractures observed in the pelvis (15.8%), the femur (14.8%) and the tibia (14.8%) (Phillips 1979). Reasons for a higher percentage of fractures found in the cranial portion of the *T. mexicana* is likely due to a combination of dense roadside habitat and the anatomy of xenarthrans whose plantigrade locomotion, coupled with short limbs, provides low agility and relatively slow locomotion (Ribeiro et al. 2017). They emerge from the forest onto the road, providing a driver with limited visibility and reaction time, and are often immediately hit by a vehicle in the frontal lateral position (Ribeiro et al. 2017).

Other reasons for xenarthrans being vulnerable to roadkill are their poor vision, which may mean they simply do not see approaching vehicles (Ribeiro et al. 2017). Furthermore, speeding vehicles and poor driver visibility (particularly in areas with dense roadside vegetation) may also influence roadkill occurrence (Collinson et al. 2019).

Similar findings for fractures found on roadkill and comparable with *T. mexicana* is a study undertaken in North America, where an average of four fractures per individual in Virginia opossums *Didelphis virginianus* were observed (Mead & Patterson 2009). This species is a medium-sized mammal, with head and body length ranging from 325 to 500 mm, weighing between 2–5.5 kg (Novak 1991) and thus similar to the *T. mexicana*. Mead & Patterson (2009) reported several findings for opossums collected on roads, where the majority of skeletal injuries occurred in the cranial portion of the skeleton (for example, 54% rib fractures and 23% scapular fractures). Similar to the findings of Mead & Patterson (2009) on opossums, we also observed more than one fracture per individual in *T. mexicana*; this is likely due to them being of medium-sized resulting in multiple fractures when colliding with a vehicle (Cross 2012).


## CONCLUSION

We found little literature evaluating long bone radiology in *T. mexicana*, therefore the data from our study which provides examples (and images) of normal appendicular x-rays plus the anatomic bone fracture location of trauma, can be used as a reference for further medical or biological studies, specifically at rescue and rehabilitation centers. Veterinarians can use epidemiological information to better understand surgical treatment of *T. mexicana* (and other species of similar size and behaviour), particularly for injured individuals that can then be rehabilitated and released back into the wild.

## REFERENCES

- Alfaro, V.C. & F.D. Quesada (2016). Registro de mamíferos silvestres atropellados y hábitat asociados en el cantón de La Fortuna, San Carlos, Costa Rica. *Biocenosis* May 17(1–2): 30.
- Artavia, A., M. Jiménez, A. Martínez-Salinas, E. Pomareda, D. Araya-Gamboa & E. Arévalo-Huezo (2015). Registro de mamíferos silvestres en la sección de la ampliación de la Ruta 32, Limón, Costa Rica. *Brenesia* 83(84): 37–46.
- Collinson, W.J., D.M. Parker, R.T. Bernard, B.K. Reilly & H.T. Davies-Mostert (2019). Factors influencing the spatial patterns of vertebrate roadkill in South Africa: The Greater Mapungubwe Transfrontier Conservation Area as a case study. *African Journal of Ecology* May: 1–13. <https://doi.org/10.1111/aje.12628>
- Cross, A.R. (2012). Fracture biology and biomechanics, pp. 595–571. In: Tobias K. & S. Johnston (eds). *Veterinary Surgery Small Animal, Vol 1*. Saunders, Missouri, 1196pp.
- De La Ossa, J. & S. Galván-Guevara (2015). Registro de mortalidad de fauna silvestre por colisión vehicular en la carretera Toluviéjo–ciénaga La Caimanera, Sucre, Colombia. *Biota Colombiana* 16(1): 67–77. <https://doi.org/10.15517/rbt.v66i2.33404>
- Martínez-Hernández, A.G., I.A. Quijano-Hernández, J. Del-Ángel-Caraza & M.A. Barbosa-Mireles (2017). Análisis de 71 casos de traumatismo en perros. *Revista Electrónica de Veterinaria* 18(2): 1–7.
- Mead, A.J. & D.B. Patterson (2009). Skeletal lesions in a population of Virginia opossums (*Didelphis virginiana*) from Baldwin county, Georgia. *Journal of Wildlife Diseases* 45(2): 325–32. <https://doi.org/10.7589/0090-3558-45.2.325>
- Minar, M., Y. Hwang, M. Park, S. Kim, C. Oh, S. Choi & G. Kim (2013). Retrospective study on fractures in dogs. *Journal of Biomedical Research* 14(3): 140–4. <https://doi.org/10.12729/jbr.2013.14.3.140>
- Molina-López, R.A., J. Casal & L. Darwich (2011). Causes of morbidity in wild raptor populations admitted at a wildlife rehabilitation centre in Spain from 1995–2007: a long term retrospective study *PLoS One* 6(9): e24603. <https://doi.org/10.1371/journal.pone.0024603>
- Monge-Nájera J. (2018a). What can we learn about wildlife killed by vehicles from a citizen science project?. A comparison of scientific and amateur tropical roadkill records. *UNED Research Journal* 10(1): 57–60. <https://doi.org/10.22458/urj.v10i1.2041>
- Monge-Nájera J. (2018b). Road kills in tropical ecosystems: a review with recommendations for mitigation and for new research. *Revista de Biología Tropical* 66(2): 722–738. <https://doi.org/10.15517/RBT.V66i2.33404>
- Navarrete, D. & J. Ortega (2011). *Tamandua mexicana* (Pilosa: Myrmecophagidae). *Mammalian Species* 43(1): 56–63. <https://doi.org/10.1644/874.1>
- Novak, R.M. (1991). *Walker's Mammals of the World, 5th Edition, Vol. I & II*. The John Hopkins University Press, Baltimore, 642pp & 1629pp.
- Ortega Reyes, J., D.G. Tirira, M. Arteaga & F. Miranda (2014). *Tamandua mexicana*. The IUCN Red List of Threatened Species 2014:e.T21349A47442649. Downloaded on 11 September 2019. <https://doi.org/10.2305/IUCN.UK.20141.RLTS.T21349A47442649.en>
- Phillips, I.R. (1979). A survey of bone fractures in the dog and cat. *Journal of Small Animal Practice* 20(11): 661–74. <https://doi.org/10.1111/j.1748-5827.1979.tb06679.x>
- Ribeiro, P., J.E. Silveira Miranda & D. Rodrigues de Araújo (2017). The effect of roadkills on the persistence of xenarthran populations: the case of the Brazilian Cerrado. *Edentata* 18: 51–61.
- Wainwright, M. (2007). *The Mammals of Costa Rica: A Natural History and Field Guide*. Cornell University Press, Ithaca, New York, 454pp.





The Journal of Threatened Taxa (JoTT) is dedicated to building evidence for conservation globally by publishing peer-reviewed articles online every month at a reasonably rapid rate at [www.threatenedtaxa.org](http://www.threatenedtaxa.org). All articles published in JoTT are registered under [Creative Commons Attribution 4.0 International License](https://creativecommons.org/licenses/by/4.0/) unless otherwise mentioned. JoTT allows unrestricted use, reproduction, and distribution of articles in any medium by providing adequate credit to the author(s) and the source of publication.

ISSN 0974-7907 (Online) | ISSN 0974-7893 (Print)

November 2019 | Vol. 11 | No. 14 | Pages: 14787–14926

Date of Publication: 26 November 2019 (Online & Print)

DOI: 10.11609/jott.2019.11.14.14787-14926

[www.threatenedtaxa.org](http://www.threatenedtaxa.org)

## Announcement

**The Sally Walker Conservation Fund -- an appeal for support**  
– P. 14787

## Communications

**Complementary bat (Mammalia: Chiroptera) survey techniques uncover two new country records for Nigeria**

– Iroro Tanshi, Anthony Ekata Ogbibu & Paul Jeremy James Bates, Pp. 14788–14801

**Bone fractures in roadkill Northern Tamandua *Tamandua mexicana* (Mammalia: Pilosa: Myrmecophagidae) in Costa Rica**

– Randall Arguedas, Elisa C. López & Lizbeth Ovaras, Pp. 14802–14807

***Barilius torsai* (Teleostei: Cypriniformes: Cyprinidae), a new freshwater fish from the Brahmaputra drainage, India**

– Kavita Kumari, Manas Hoshalli Munivenkatappa, Archana Sinha, Simanku Borah & Basanta Kumar Das, Pp. 14808–14815

**Butterfly diversity throughout Midnapore urban area in West Bengal, India**

– Surjyo Jyoti Biswas, Debarun Patra, Soumyajit Roy, Santosh Kumar Giri, Suman Paul & Asif Hossain, Pp. 14816–14826

**Plant and fungi diversity of Devi Pindiyan Valley in Trikuta Hills of northwestern Himalaya, India**

– Sajjan Thakur, Harish Chander Dutt, Bikarma Singh, Yash Pal Sharma, Nawang Tashi, Rajender Singh Chakraborty, Geeta Sharma, Om Prakash Vidyarthi, Tasir Iqbal, Bishander Singh & Kewal Kumar, Pp. 14827–14844

**A checklist of rust fungi from Himachal Pradesh, India**

– Ajay Kumar Gautam & Shubhi Avasthi, Pp. 14845–14861

**The distribution of blue-green algae (Cyanobacteria) from the paddy fields of Patan and Karad tehsils of Satara District, Maharashtra, India**

– Sharada Jagannath Ghadage & Vaneeta Chandrashekar Karande, Pp. 14862–14869

## Short Communications

***Cordia diffusa* K.C. Jacob, the Kovai Manjack (Boraginaceae): a highly threatened steno-endemic species from Coimbatore City, Tamil Nadu, India**

– S. Arumugam, K. Sampath Kumar, B. Karthik & V. Ravichandran, Pp. 14870–14875

**New distribution records in the orchid flora of Tripura, India**

– Arjun Adit, Monika Koul & Rajesh Tandon, Pp. 14876–14885

**Notes on the extended distribution of *Humboldtia bourdillonii* (Fabales: Fabaceae), an Endangered tree legume in the Western Ghats, India**

– Anoop P. Balan, A.J. Robi & S.V. Predeep, Pp. 14886–14890

## Notes

**Vertebrate prey handling in the Indian Grey Hornbill *Ocyrceros birostris* (Aves: Bucerotiformes: Bucerotidae)**

– James A. Fitzsimons, Pp. 14891–14894

**Impact of cyclone Fani on the breeding success of sandbar-nesting birds along the Mahanadi River in Odisha, India**

– Subrat Debata, Pp. 14895–14898

**First record of the micromoth *Ethmia lineatonotella* (Moore, 1867) (Lepidoptera: Depressariidae: Ethmiinae) from Bhutan**

– Jatishwor Singh Irungbam & Meenakshi Jatishwor Irungbam, Pp. 14899–14901

**Additional distribution records of the rare Nepal Comma**

***Polygonia c-album agnicula* (Moore, 1872) (Insecta: Lepidoptera: Nymphalidae) from Rara National Park, Nepal**

– Sanej Prasad Suwal, Biraj Shrestha, Binita Pandey, Bibek Shrestha, Prithivi Lal Nepali, Kaashi Chandra Rokaya & Bimal Raj Shrestha, Pp. 14902–14905

**A new distribution record of the gall midge *Octodiplosis bispina* Sharma (Diptera: Cecidomyiidae) from the Western Ghats of Tamil Nadu, India**

– Duraikannu Vasanthakumar, Radheshyam Murlidhar Sharma & Palanisamy Senthilkumar, Pp. 14906–14907

**New recruitment of staghorn corals in the Gulf of Mannar - the emergence of a resilient coral reef**

– Koushik Sadhukhan, Ramesh Chatragadda, T. Shanmugaraj & M.V. Ramana Murthy, Pp. 14908–14911

**New records of coral diseases in the Persian Gulf**

– Parviz Tavakoli-Kolour & Sanaz Hazraty-Kari, Pp. 14912–14913

***Crepidium aphyllum* (Orchidaceae), a new record from Bhutan**

– Kinley Rabgay & Pankaj Kumar, Pp. 14914–14916

**Rediscovery, after over a century, of the endemic climbing vine *Argyreia lawii* (Convolvulaceae) from the Western Ghats of India**

– Pramod R. Lawand, Rajaram V. Gurav & Vinod B. Shimpale, Pp. 14917–14920

***Linostoma decandrum* (Roxb. ) Wall. ex Endl. (Thymelaeaceae): an addition to the flora of Andaman Islands, India**

– L. Rasingam & K. Karthigeyan, Pp. 14921–14922

**On the floral biology and pollination of a rare Twining Liana *Sarcolobus carinatus* Wall. (Asclepiadoideae: Apocynaceae) in Coringa Mangrove Forest, Andhra Pradesh, India**

– A.J. Solomon Raju, Pp. 14923–14926

## Partner



صندوق محمد بن زايد  
للمحافظة على  
الكائنات الحية  
The Mohamed bin Zayed  
SPECIES CONSERVATION FUND

## Member



## Publisher & Host

